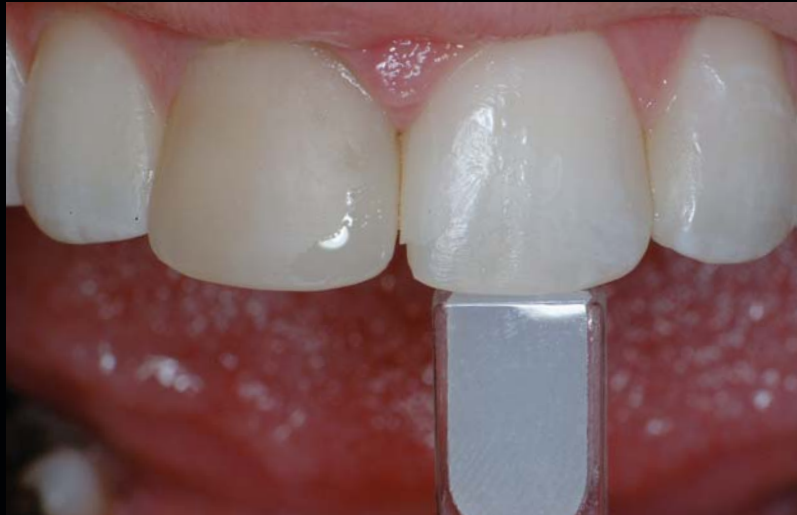

A POLYCHROMATIC COMPOSITE LAYERING APPROACH FOR SOLVING A COMPLEX CLASS IV/DIRECT VENEER-DIASTEMA COMBINATION: PART I

Newton Fahl, Jr, DDS, MS*



Direct resin bonding represents a conservative means of providing aesthetic restoration of the anterior dentition. Such techniques enable chairside control of colors, morphology, and ultimately, aesthetic results. For optimal integration, the clinician must thoroughly understand the capabilities of resin materials and their behavior when layered in direct resin buildups. This article demonstrates an advanced clinical technique for enhancing the appearance of the anterior dentition as achieved via tooth whitening and a combination of a Class IV restoration and a direct resin veneer.

Learning Objectives:

This article discusses a conservative treatment option for restoring a fractured, discolored single anterior tooth via a combination of a direct veneer, Class IV, and diastema closure restoration. Upon reading this article, the reader should:

- Become familiar with both a treatment plan and a clinical procedural protocol that ensure the predictable attainment of aesthetically and functionally biointegrated direct anterior composite restorations.
- Be able to understand the fundamentals that lead to correct composite resin selection and implementation to impart life like results.

Key Words: adhesive, composite, conservative, veneer, Class IV, diastema

*Private practice, Curitiba, Brazil.

Newton Fahl, Jr, DDS, Av. Visconde do Rio Branco, 1335, Suites 23/24, 80420-210
Curitiba, Brazil
Tel: +55-41-252-3749 • E-mail: fahl@fahl.com.br

In recent years, the physical and optical properties of composite resin materials have been enhanced to the point where they often represent a first-line therapeutic approach.^{1,5} The indications for the use of composite resin procedures have increased accordingly and presently include fractured, discolored teeth, diastema closure, and many others (eg, correction of form, malpositioned teeth). As a result of the involved preparation requirements and their ability to be effectively controlled chairside, composite resins such as microfills, microhybrids, and nancomposites (eg, Venus, Heraeus Kulzer, Armonk, NY; Filtek, 3M Espe, St. Paul, MN; 4 Seasons, Ivoclar Vivadent, Amherst, NY) can represent a more conservative treatment option than indirect restorations. Through direct resin stratification, clinicians can achieve control of color and morphology in a way very similar to what is accomplished with ceramics by experienced master dental ceramists.⁶ This article presents several fundamentals of resin selection and color matching needed for clinical success. It also demonstrates an advanced direct resin technique for enhancing the appearance of the anterior dentition as achieved via tooth whitening and a combination of a Class IV restoration and a direct resin veneer—representing a polychromatic composite layering approach.

Resin Selection and Color Mapping

The key element in shade selection is the clinician's ability to visualize the color and histological determinants of the natural dentition to be emulated, and then correlate them with the restorative resins.⁷ The perceived color of a tooth is, in actuality, a combination of an inner substrate (ie, dentin) and an outer substrate (ie, enamel), and is also known as the composite tooth color.⁸ Each bears

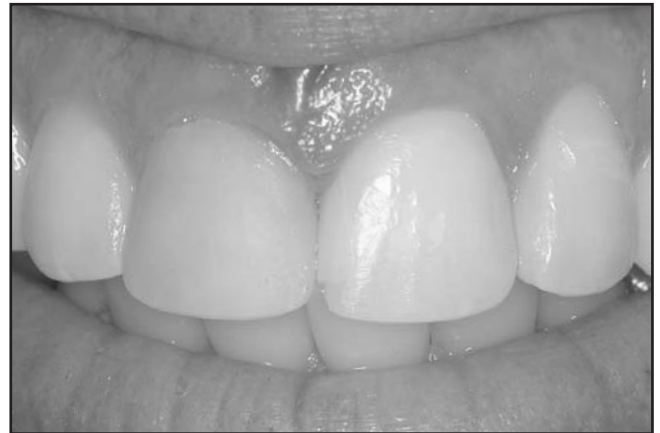

Figure 2. The low value is evident through the use of black and white photography.

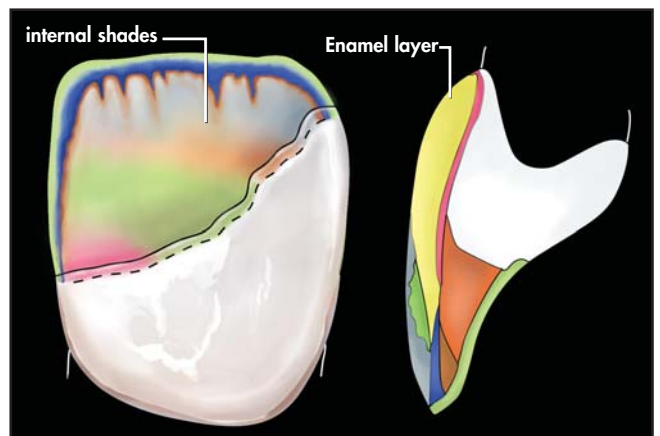


Figure 3. Artificial body enamel, artificial dentin, and artificial effect enamel shades, respectively, were selected to compose the strata of the polychromatic restoration. A color map was produced to aid during the restorative stage.

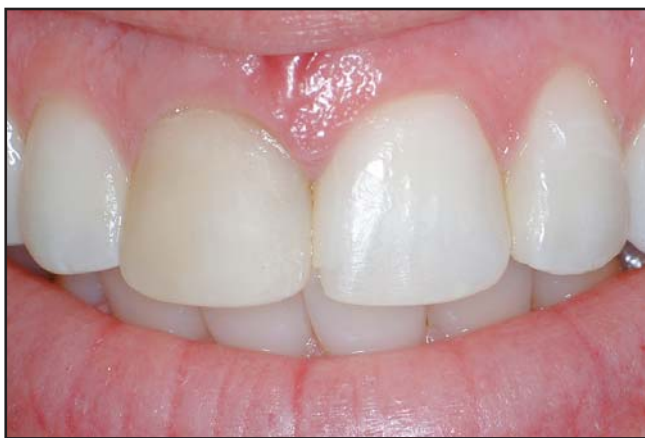

Figure 1. Postbleaching view of the smile depicting a defective Class IV/veneer composite restoration.

its intrinsic physical and optical properties that must be understood individually and collectively. Dentin is approximately 20% more opaque than enamel⁹ and is responsible for providing most of the hue of a tooth, which falls in the red-yellow spectra.¹⁰ Enamel is but a fiber optic layer that modulates the perception of the underlying dentin color.¹¹ The degree of translucency/opacity of enamel can vary according to natural factors such as thickness, genetics, and age as well as operative-induced factors such as tooth bleaching.¹² Such variances can determine one's perception of the underlying dentin color, thereby altering its chroma and value. Highly translucent enamel permits light to be transmitted through it to reach a deeper, high-chroma dentin substrate and reflects most of its hue without much change in color saturation. This circumstance provides an enamel of lower

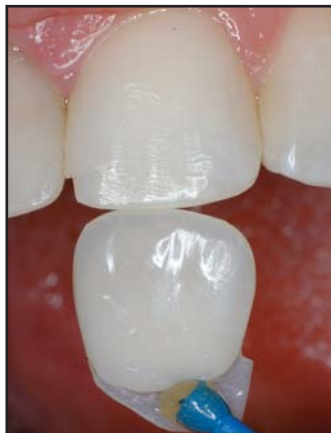

Figure 4. A color mock-up is created to replicate the varying thicknesses, shade, and optical properties of the definitive restoration.

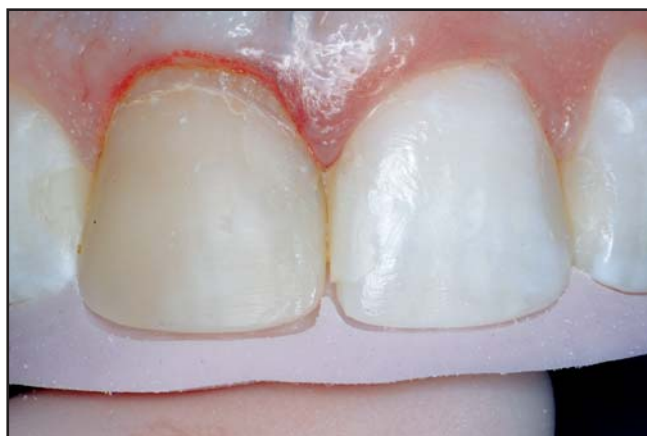

Figure 5. A putty PVS matrix was obtained from a previously waxed-up model in order to aid in the three-dimensional perception of the defect boundaries.

color value. On the other hand, more opacious enamel acts as a barrier that disperses, absorbs, and reflects the light in such a way that a minimal amount of color (ie, hue, chroma) is visualized. This situation determines an enamel of higher value.

The oxidation process of bleaching affects mostly enamel but also reacts with dentin to some extent, thereby decreasing some of its chroma.¹³ Although bleached teeth usually reveal more opacious enamels of high value and dentins with lower chroma, it is still possible to see the dentin color showing through the somewhat achromatic enamel. These are paramount factors to consider when restoring bleached teeth.

The composite resin armamentarium necessary for treating medium-sized Class IV restorations and directly veneering a discolored tooth are classified as follows:

- Artificial dentin – a higher chroma, slightly lower value, opacious composite to be used to emulate the missing natural dentin as per its optical and physical properties;
- Artificial body enamel – an enamel-like composite bearing hue with a lower chroma and slightly higher value than the underlying artificial dentin composite. In the case of bleached dentitions, its chroma can be almost imperceptible;
- Artificial translucent effect enamel – a translucent composite of varying degrees of translucency and hues (eg, gray, blue, violet) used to impart depth in areas such as the incisal third;
- Artificial milky white semitranslucent effect enamel – a semitranslucent composite of higher opacity and value than the translucent enamel, which can be used to replicate the lingual enamel contours (ie, lingual shelf) and to create halo effects. It can also present a wide range of tones (ie, from snow-white to amber-white);
- Artificial value effect enamel – a non-VITA-based enamel that can range from translucent to opacious and that is used as a final layer to modify or corroborate an existing value of the body enamel. It is used to seal characterizations and maverick colors underneath it; and
- Opaquing agent – usually an opaquer that is used in conjunction with other enamel and dentin layers to alter the value of a discolored substrate.

Case Presentation

Clinical Examination and Treatment Planning

A 33-year-old patient presented with a request for smile improvement (Figures 1 and 2). Clinical examination

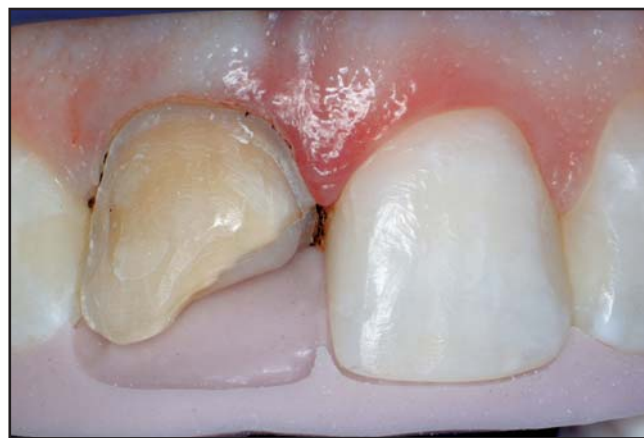

Figure 6. Determination of incisal edge position, embrasure forms, and palatal anatomy is paramount through this approach.

revealed a compromise in color as well as in shape. Vital in-office and home bleaching was proposed and carried out. Forty-five days after the completion of the bleaching therapy,¹⁴ additional clinical examination revealed defective old composite restorations on the right and left maxillary central incisors. The width-height proportion of the right central incisor showed an incorrect ratio¹⁵ and was asymmetrical to that of the left central incisor because of a gingival architecture discrepancy. Tooth #8(11) was endodontically treated and exhibited a faulty direct veneer/Class IV combination. Tooth #9(21) demonstrated a defective composite restoration on its mesial aspect, which concealed a minute diastema between the central incisors.

The treatment of choice involved replacement of the faulty restorations with direct composite restorations. Factors influencing this decision included the conservative nature of the procedure (ie, minimal to no tooth preparation) and the ability of the operator to deliver artistic composite restorations that could rival the aesthetics of laboratory-processed ceramic restorations (eg, porcelain veneer, crown). In addition, the therapeutic approach was deemed sufficient to replicate the functional integrity of the endodontically treated tooth.¹⁶

Artificial body enamel, artificial dentin, and artificial effect enamel shades, respectively, were selected to compose the strata of the polychromatic restoration and a color map was produced to aid during the restorative stage (Figure 3). Customized shade tabs¹⁷ were used in the selection process, as opposed to a VITA Lumin or the restorative resin's own shade guide, because of the color discrepancy that can be perceived between commercially available shade guides and the actual composite resin.¹⁸ Based on the selected shades, a color mockup was created to replicate the varying thicknesses, shade, and optical properties of the definitive restoration.¹⁹ Any mismatches in hue, chroma, value, translucency, and opacity were ascertained at this stage for further correction (Figure 4). Once the biologic width was evaluated, an electrosurgical unit was utilized to perform soft tissue recontouring.

A putty polyvinylsiloxane (PVS) matrix was obtained from a previously waxed-up model in order to aid in the three-dimensional perception of the defect boundaries (ie, determination of incisal edge position), embrasure forms, and palatal anatomy (Figures 5 and 6). Similarly, a labial PVS guide was created and used throughout the veneer preparation to gauge the appropriate amount of tooth reduction.²⁰ Due to the severity of the discoloration of the substrate, approximately 1.2 mm of space was obtained through the preparation technique for the realization of the direct veneer. Additionally, a 2-mm-long and 1-mm-thick bevel was placed along the fracture line

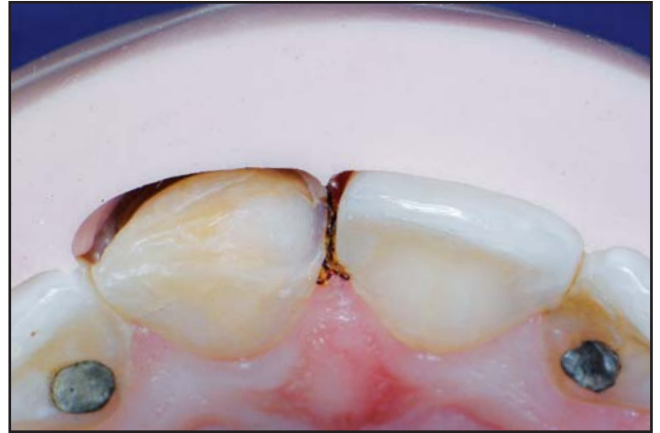

Figure 7. A PVS guide is created and used throughout veneer preparation to gauge amount of tooth reduction.

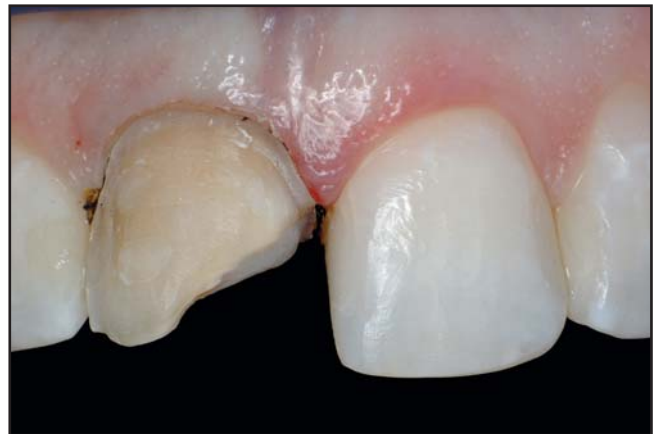

Figure 8. Class IV restoration/veneer preparation is completed, revealing a challenging situation both from a color and contour point of view.

to aid in the concealment of the tooth-composite transition²¹; this would allow for the application of a greater thickness of composite with similar optical properties to the natural dentin. As the middle third of a central incisor would be subjected to the highest tensile stress upon function,²² a 1-mm-long and 1-mm-thick chamfer was placed palatally, instead of a bevel, to allow for a thicker layer of composite at the tooth-restoration junction. In this author's opinion, this preparation concept might promote better marginal integrity and longevity.

A nonimpregnated cord was packed into the gingival sulcus, thereby retracting the free gingival margin to approximately 0.5 mm. A chamfer preparation was subsequently carried to the gingival level and the Class IV/veneer preparation was completed (Figures 7 and 8). A sandblaster with 30- μ m silanated ceramic particles was used to enhance micromechanical and chemical

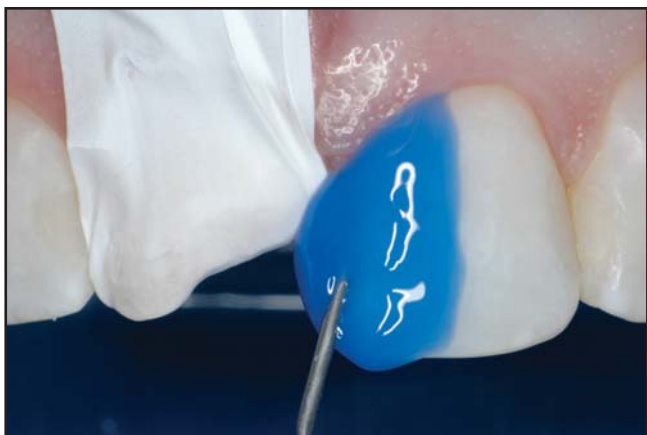

Figure 9. Teflon tape protects the adjacent tooth during acid etching. After air-drying, a bonding agent was applied and light cured.

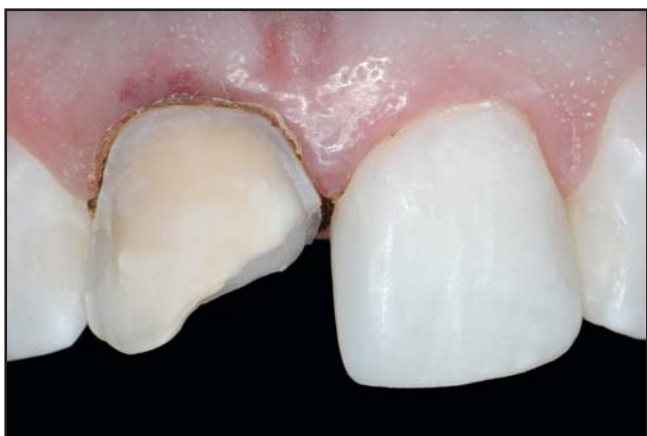

Figure 10. Postoperative view of the definitive restoration on tooth #9. Primary anatomy and the exact mesiodistal width are achieved.

retention between the existing composite and the new restoration of tooth #8. Sandblasting also removed the aprismatic enamel of the proximal, and partially labial and palatal aspects of tooth #9.²³ A 35% phosphoric acid was used for 15 seconds on enamel and rinsed off. After air-drying, a bonding agent was applied and light cured (Figures 9 and 10).

Conclusion

Achieving long-term, natural-looking aesthetics in the anterior zone can be a challenging feat for many dental professionals to achieve. Knowledgeable and skilled clinicians can perform adhesive direct procedures so as to mimic the physical and optical characteristics of the natural dentition. The first part of this two-part article discussed the use of whitening, color mapping, and

proper resin selection, as a means toward achieving success in the aesthetic zone. Part II will provide a thorough presentation of an advanced polychromatic composite layering technique and how it was used to meet the patient's expectations.

Acknowledgment

The author declares no financial interest in any of the products referenced herein.

References

1. Dietschi D. Free-hand composite resin restorations: A key to anterior aesthetics. *Pract Periodont Aesthet Dent* 1995;7(7):15-25.
2. Vanini L, De Simone F, Tammaro S. Indirect composite restorations in the anterior region: A predictable technique for complex cases. *Pract Periodont Aesthet Dent* 1997;9(7):795-802.
3. Magne P, Holz J. Stratification of composite restorations: Systematic and durable replication of natural aesthetics. *Pract Periodont Aesthet Dent* 1996;8(1):61-68.
4. Fahl N Jr. Achieving ultimate anterior esthetics with a new micro-hybrid composite. *Compend Contin Educ Dent Suppl* 2000; 26:4-13.
5. Baratieri, Luiz N. *Estética—Restaurações Adesivas Diretas em Dentes Anteriores Fraturados*. 1st ed. São Paulo, Brazil: Quintessence Publishing; 1995.
6. Chiche GJ, Aoshima H. *Smile Design: A Guide for Clinician, Ceramist, and Patient*. Hanover Park, IL: Quintessence Publishing Co, Inc; 2004.
7. Fahl N Jr, Denehy GE, Jackson RD. Protocol for predictable restoration of anterior teeth with composite resins. *Pract Periodont Aesthet Dent* 1995;7(8):13-21.
8. Muia PJ. *Esthetic Restorations Improved Dentist—Laboratory Communication*. Carol Stream, IL: Quintessence Publishing Co, Inc; 1993.
9. Vargas MA, Lunn PS, Fortin D. Translucency of human enamel and dentin. *J Dent Res* 1994; AADR Abstracts(Abstract No. 1747).
10. Vanini L, Mangani F, Klimovskaia O. Il restauro conservativo dei denti anteriori - ACME sas, Viterbo, Italy; 2005.
11. Muia PJ. *Four Dimensional Color System*. Chicago, IL: Quintessence Publishing Co, Inc; 1993.
12. Kishita-Derani M, Neiva GF, Yaman P, Dennison JB. Evaluation of tooth color change using four paint-on tooth whiteners - IADR 2005;(Abstract No. 61931).
13. Dahl JE, Pallesen U. Tooth bleaching—A critical review of the biological aspects. *Crit Rev Oral Biol Med* 2003;14(4):292-304.
14. Cavalli V, Reis AF, Giannini M, Ambrosano GM. The effect of elapsed time following bleaching on enamel bond strength of resin composite. *Oper Dent* 2001;26(6):597-602.
15. Chiche G, Pinault A. *Esthetics of Anterior Fixed Prosthodontics*. Chicago, IL: Quintessence Publishing Co, Inc; 1994.
16. Reeh ES, Douglas WH, Messer HH. Stiffness of endodontically-treated teeth related to restoration technique. *J Dent Res* 1989;68(11):1540-1544.
17. Fahl N Jr. Shade matching in anterior composite restorations: Learning from failures to ensure success. *Seattle Study Club* 2005;10(2):17-26.
18. Fahl N Jr. Veneers—direct/indirect resin. In: Miller MB, ed. *Reality*. Vol 25. Houston, TX: Reality Publishing; 2001:3-289-3-295.
19. Fahl N Jr. Bringing composite resins to an art form in the anterior segment. *Australasian Dent* 2006;15(4):58-60.
20. Gürel G. *The Science and Art of Porcelain Laminate Veneers*. Hanover Park, IL: Quintessence Publishing Co, Inc; 2003.
21. Fahl N Jr. Trans-surgical restoration of extensive Class IV defects in the anterior dentition. *Pract Periodontics Aesthet Dent* 1997; 9(7):709-720.
22. Magne P, Belser U. *Bonded Porcelain Restorations in the Anterior Dentition: A Biomimetic Approach*. Hanover Park, IL: Quintessence Publishing Co, Inc; 2002.
23. Carvalho RM, Santiago SL, Fernandes CA, et al. Effects of prism orientation on tensile strength of enamel. *J Adhes Dent* 2000;2(4): 251-257.

CONTINUING EDUCATION (CE) EXERCISE No. X



To submit your CE Exercise answers, please use the answer sheet found within the CE Editorial Section of this issue and complete as follows: 1) Identify the article; 2) Place an X in the appropriate box for each question of each exercise; 3) Clip answer sheet from the page and mail it to the CE Department at Montage Media Corporation. For further instructions, please refer to the CE Editorial Section.

The 10 multiple-choice questions for this Continuing Education (CE) exercise are based on the article "A polychromatic composite layering approach for solving a complex class IV/direct veneer-diastema combination: Part I," by Newton Fahl, Jr, DDS, MS. This article is on Pages 000-000.

1. Once the biologic width was evaluated, what was utilized to perform soft tissue recontouring?
 - a. A laser.
 - b. An LED light curing unit.
 - c. An electrosurgical unit.
 - d. A finishing bur.
2. What shade set was used in the selection process of this case?
 - a. VITA Lumin.
 - b. Customized shade tabs.
 - c. Restorative resin's own shade guide.
 - d. None of the above.
3. A PVS matrix was obtained from a previously waxed-up model to aid in the 3-D perception of what?
 - a. Defect boundaries.
 - b. Embrasure forms.
 - c. Palatal anatomy.
 - d. All of the above.
4. Due to the severity of the discoloration of the substrate, approximately how many millimeters of room were obtained through the preparation technique?
 - a. 0.5.
 - b. 1.0.
 - c. 1.2.
 - d. 1.5.
5. A nonimpregnated cord was packed into the gingival sulcus. This retracted the free gingival margin to approximately 0.7 mm.
 - a. Only the first statement is true.
 - b. Only the second statement is true.
 - c. Both statements are true.
 - d. Neither statement is true.
6. In this case, what did the sandblasting remove?
 - a. Aprismatic enamel of the proximal.
 - b. Partially labial aspects of the tooth.
 - c. Partially palatal aspects of the tooth.
 - d. All of the above.
7. The contoured layer was initially spot-cured with a LED curing unit for what length of time?
 - a. 3 seconds.
 - b. 7 seconds.
 - c. 5 seconds.
 - d. 9 seconds.
8. The etchant was rinsed with copious water spray. Excess water was aspirated until the dentin surface presented moist.
 - a. Only the first statement is true.
 - b. Only the second statement is true.
 - c. Both statements are true.
 - d. Neither statement is true.
9. As a chroma variance was perceived at the shade selection phase, how many artificial dentin shades were selected to impart the chroma gradient desired?
 - a. 2.
 - b. 4.
 - c. 3.
 - d. 5.
10. The natural dentition dehydrates during the restorative phase and the value is elevated. This makes it impossible to relate to the adjacent teeth for value check.
 - a. Only the first statement is true.
 - b. Only the second statement is true.
 - c. Both statements are true.
 - d. Neither statement is true.